

Comparison between the Effect of Bisphosphonates and Concentrated Growth Factors on Bone Healing Experimental Study

Mohammed A. Naji¹, Rana M. Nagah², Fakhreldin H. Abdel-Rahman³, Hamdy A. Marzook⁴

Abstract:

Objective: Objectives: The aim of study was to compare the histological effect of Bisphosphonates (BPH) and Concentrated growth factors (CGFs) in bone defect healing. **Materials and Methods:** This experimental trial was conducted on 8 adults healthy New Zealand male rabbits weighing (2–3kgs). The rabbits are grouped as following: 4 rabbits in the CGF group and 4 rabbits in the BPH group and then sub-grouped according to sacrifice time into 2 and 4 weeks in each rabbit. Two circular bone defects were created in the tibia (so every group have 8 defect). After that, each rabbit was treated by either BPH or CGF. Four rabbits were sacrificed at each of the experimental periods 2 and 4 weeks postoperatively. The right tibia from each animal was immediately removed, fixed with 10% neutral buffered formalin, and dematerialized with Ethylene Diamine Tetra Acetic acid (EDTA). After the complete demineralization, the tibias were processed to H&E and trichrome staining. After that, histological compare the healing between the two groups. **Results:** Histological evaluation showed more mature bone formation in the CGFs groups compared to BPH groups. In addition, CGFs groups showed favorable regeneration of bone. Histologically, the bone formation in CGFs groups was higher than in the BPH groups. **Conclusions:** The current study found that proper application of Concentrated growth factors CGF as an osteoconductive material gave better enhancement in osteogenesis and acceleration in bone healing than Bisphosphonates BPH.

Introduction:

In many cases involving extended periods of tooth loss, alveolar bone grafting is required before or during oral implant placement. Sinus lift techniques and socket preservation procedures require biomaterials capable of inducing fast and effective wound healing and bone regeneration.¹ Since autologous bone grafting is associated with considerable morbidity and the single use of biomaterials still requires long healing processes.²

Bisphosphonates (BPH) are the treatment of choice for some skeletal diseases such as osteogenesis imperfecta, fibrous dysplasia, multiple myeloma, bone tumors, breast and prostate cancers, Paget's disease, and osteoporosis with low bone mineral density (BMD) in postmenopausal women, male hypogonadism, Crohn's disease and in patients consuming excessive glucocorticoids.³

Concentrated growth factors (CGFs) are the driving force for tissue regeneration by regulating many aspects of cellular behavior, the function of which has been widely accepted. The platelet rich fibrin (PRF) derivatives developed by Sacco in 2006.⁴ It consists of a collection of many components, for example, Transforming growth factor-beta (TGF- β) and insulin-like growth factor promote cell proliferation; TGF- β and vascular endothelial growth factors (VEGF) enhance cell migration; bone morphogenetic proteins (BMPs) and fibroblast

growth factor 2 (FGF2) stimulate osteogenic differentiation; VEGF and platelet-derived growth factor (PDGF) are essential in the process of angiogenesis.⁵⁻⁷ Native growth factors are embedded within the extracellular matrix (ECM). However, exogenous growth factors applied alone in tissue engineering have a short life due to rapid proteolysis.⁵ Many articles have been published on the application of CGFs in the dental and maxillofacial fields.⁴ This study was performed in order to compare the effect of bisphosphonates versus CGF in bone healing.

Materials and Methods:

Animals:

Sixteen rabbits (New Zealand white adult males) weighting (2 – 3kgs) were utilized in the current study. All animals were kept in the same nutritional and environmental conditions. The study protocol was accepted by the ethical committee of the Faculty of Dentistry, Mansoura University, Egypt. The housing of rabbits was in a room with a 12/12 hours light-dark cycle at a temperature 22°C and 65-70% relative humidity. Animals were fed a commercial diet and water.

Study design:

Sixteen rabbits were used in the current work. In each rabbit, two bone cavities were prepared in the right tibia. Rabbits were randomly allocated into equal two groups; BPH Group: the bone defects were prepared then treated with Bisphosphonate and CGF Group: the bone defects were prepared then treated by CGF.

Bisphosphonate's preparation:

Bisphosphonate was prepared by dissolving 20mg. Fosamax (Aesica Ph. GmbH-Germany) in 1ml normal saline which in a glass cup, then transferred by spatula into the defects.⁶

¹Postgraduate MSc student, Department of Oral and Maxillofacial Surgery, Faculty of Dentistry, Mansoura University, Egypt.

Corresponding author: mamn2006dr@gmail.com

²Lecturer, Department of Oral Biology, Faculty of Dentistry, Mansoura University, Egypt.

³Lecturer, Department of Oral and Maxillofacial Surgery, Faculty of Dentistry, Mansoura University, Egypt.

⁴Professor Emeritus, Department of Oral and Maxillofacial Surgery, Faculty of Dentistry, Mansoura University, Egypt.

doi: 10.21608/MJD.2022.259763

CGF preparation:

Whole blood was drawn from the marginal ear vein in a 10-ml tube containing no anticoagulant. Then CGF was prepared according to the protocol described by Mourão et al.⁷ Following a series of centrifugation speeds and time. Which resulted in the formation of 3 layers top platelet poor plasma, the middle layer of fibrin gel with concentrated growth membrane, and lower RBCs layer. The middle layer was obtained using forceps and separated from other layers using a scalpel.

Anesthesia:

The rabbits were subjected to systemic anesthesia by intramuscular injections of xylazine 25mg/kg (ADWIA Company, 10th of Ramadan city_ Egypt), ketamine-HCl (TROIKA pharmaceutical ltd., India) 20mg/kg, and diazepam 0.5mg/kg (L: Manufactured by Alexandria Co, Egypt), and in the proximal right and left tibia.⁸

Surgical techniques:

Firstly, the surgical site was shaved and rubbed with a povidine-iodine disinfectant (Nile Company for Pharmaceuticals and Chemical Industries - Cairo - Egypt), (Figure1, A). Next, at the surgical site, cutaneous incisions were made 2 cm below the knee and 4 cm in diameter. The fascia was cut. Then the tibial periosteum was reflected to reach the bone, (Figure1, B). 2 bony defects (3 mm in diameter and 6 mm in depth) were prepared by using trephine bur (medesy Italy) of 3mm diameter in the right tibia in each rabbit⁹, (Figure1, C). After that, both bone defects were irrigated with saline (EL-NILE Company for pharmaceutical and chemical industries- Cairo -Egypt) by a 5ml syringe to remove the debris and dry. After that defect is filled with BPH or CGF, (Figure1, G, and H). Then, the wound was sutured in layers using 3/0 restorable vicryl (assut sutures 3/0 Switzerland), (Figure1, D). The rabbits were given antibiotics ceftriaxone (E.I.P.I.CO. 10Ramadan City -Industry-Egypt) at 5 mg/kg IM 2 times per day for five days and analgesia by diclofenac sodium (Novartis group co. Egypt) 2 mg/kg post-surgery for three days postoperatively.¹⁰

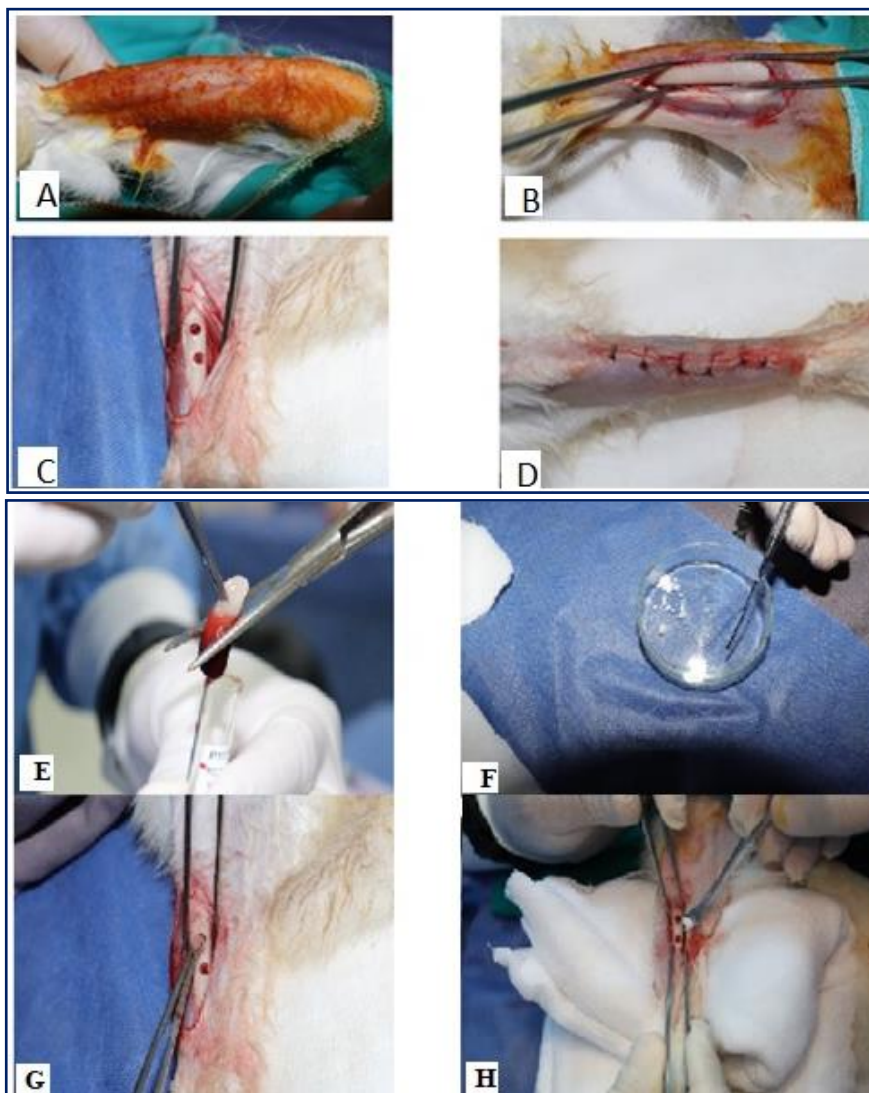


Figure 1: Photographs showing Steps of surgical procedure (A) Surgical sites Shaved and draped with povidone-iodine (B) Bone exposed (C) Bone defect (D) Sutured surgical side (E) CGF after preparation (F) BPH preparation (G) CGF application (H) BPH application

Assessment:

For post-operative assessment, eight rabbits have sacrificed two rabbits from each group at the experimental periods 2 and 4 weeks postoperatively using a high dose of diethyl ether. The right tibia from each animal was immediately removed, fixed with 10% neutral buffered formalin, and embedded in EDTA for demineralization. After the complete demineralization, the tibias were placed in paraffin block in the Mansoura University, faculty of medicine, pathology department, and prepared for histological examination by:

1. Hematoxylin and Eosin stain (H&E) as a routine stain to assess the newly regenerated bone.
2. Masson's trichrome staining for detection of newly formed collagen fibers and extent of mineralization.

Results:

Histological analysis: After 2 weeks

The microscopic examination of the histological slides in 2 groups showed no new bone formation. The old bone showed classic lamellar bone histology with multiple osteons. Each formed of centrally located Haversian canal with osteocytes lacunae ranged circumferentially around it with a remnant of older osteons between them.

(Bisphosphonates treated group) after 4 weeks:

The histological slides of the BPH group showed the formation of new bone with thinner bone trabeculae radiating from old bone and wider bone marrow spaces when compared to the CGF group. The quality and quantity of newly formed bone are lower in the BPH group when compared to the CGF group. Bone trabeculae contained scattered osteocytic lacunae. A complete osseous fusion was observed between old and new bone, (Figure 2, A). In trichrome slides the collagen fiber was marked by the blue coloration, more formation, and more maturation in the CGF group when compared to the BPH group, (Figure 2, C).

CGF treated group after 4 weeks:

The histological slides of the CGF group showed the formation of new bone, which was found to contain bone trabeculae with greater thickness, a better arrangement which was confirmed by the formation of new osteons, separated by areas of woven bone and in-between smaller bone marrow spaces, unlike bisphosphonate group. The quality and quantity of newly formed bone are better in the CGF group when compared to the BPH group. A complete osseous fusion was observed between old and new bone, (Figure 2, B). In trichrome slides the collagen fiber was marked by the blue coloration less formation and less maturation in the BPH group when compared to the CGF group, (Figure 2, D).

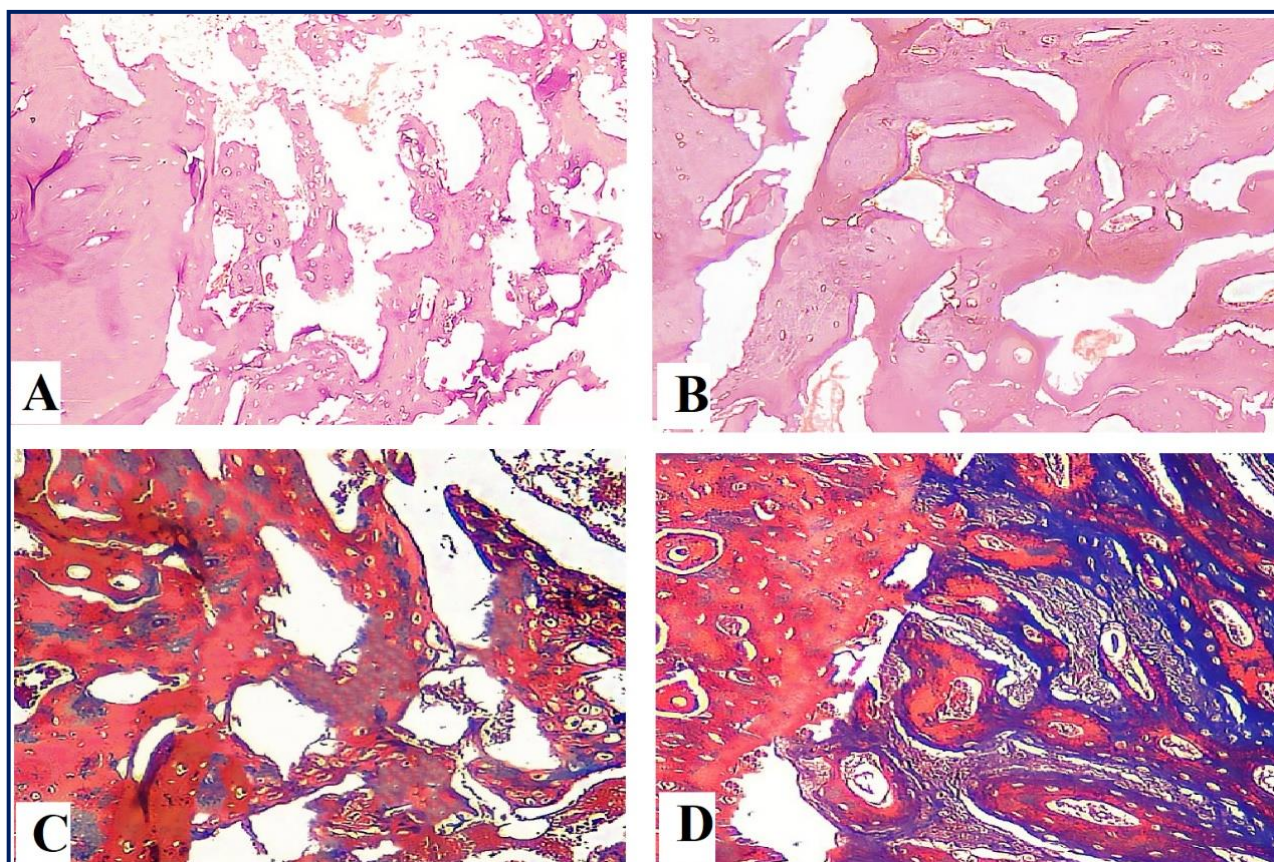


Figure 2: Histological slides photograph A) H&E stain of BPH showing less amount of the newly formed bone trabeculae (H&E X100), B) H&E stain of CGF showing more amount of newly formed bone trabeculae (H&E X100), C) Trichrome stain of BPH showing less arranged of osteoblast forming cells (MTC X100), D) Trichrome stain of CGF showing more arrangement of osteoblast cell (MTC X100)

Discussion:

Bone defects are one of the most common problems in treating diseases. It is a result of surgical evacuation of the cysts, removing of impacted teeth, injuries, post-extraction sockets, and periodontal diseases or osteoporosis that may need a long time to heal.¹¹ In order to compensate for lost bone and stimulate healing, such bone grafts, calcium phosphates graft, and other approaches were tested with variable degrees of success in regenerating bone.

BPH is a medication that is known to decrease bone resorption by osteoclasts deactivation.¹² CGF also plays a role in increasing the rate of bone healing by enhancing extracellular matrix (ECM) formation and increasing movements, differentiation, and multiplications of osteoblast cells.

The result of H&E slides of 2 groups after two weeks showed no new bone formation that was consistent with the study conducted by Oktay, et al.¹³ reported that the healing connective tissue replacement by connective tissue after 56 days of follow-up.

In bisphosphonates, BPH treated groups, and four weeks subgroups showed the formation of bone with thin trabeculae separated by wide marrow spaces compared to CGF groups.

So, the quality and quantity of newly formed bone in BPH groups were found to be less than that in CGF groups which were consistent with the study presented by Lang et al.¹⁴ who stated that bisphosphonates inhibit the endothelial cell from proliferation.

However, Yu et al.¹⁵ reported that local application of bisphosphonate improves bone fracture healing by inhibiting osteoclast formation, thus inhibiting bone resorption.

In CGF treated groups, four weeks subgroups showed the formation of new bone, which was found to contain bone trabeculae with greater thickness, a better arrangement which was confirmed by the formation of new osteons, separated by areas of woven bone and in-between smaller bone marrow spaces. The study conducted by Chen et al.¹⁶ showed that CGF significantly increased bone formation against harmful effects of bisphosphonates.

However, these results were not consistent with the findings of Durmuşlar et al.¹⁷ who reported that a small amount of new bone formed was observed with CGF.

Masson trichrome stained sections showed more collagen fibers and a higher degree of mineralization in CGF groups compared to BPH groups which might be explained by the fact stated by Hauser et al.¹⁸ who reported that bisphosphonates BPH delayed healing in bone defect and caused a delay in healing in mechanically compromised situations. So, the formed bone in the BPH group was immature compared with

that of CGF groups marked by blue coloration reflecting collagen content and red coloration reflecting mineralization.

That was also in agreement with Sahin et al.¹⁹ who reported that the CGF can efficiently stimulate the proliferation and differentiation of osteoblast cells, thereby improving the healing process.

Because the BPH action on osteoclast at the remodeling stage of bone healing and the CGF on osteoblast at repair and remodeling stage of bone healing and the healing process in the bone defect in the synthesis of bone processes rather than remodeling the bone formation in the CGF group is more than in BPH group, that was consistent with the study conducted by Yüce et al.²⁰

The limitation of this study include the study was done to compare the effect of the two substances on the bone healing, and without control group and small sample size as our paper as many study done by Stavropoulos et al.²¹, Simion et al.²² and Schorn et al.²³ No statistics analysis done because the aim of study to confirm new bone formation and compare the effect of the BPH and CGF on that as primary study need to more studies and Trichrome stain was done to confirmed the amount of collagen formed and mineralization of the new bone. Because the sample size is small and the time is short, we recommend conducting a study with larger sample size and a longer time to confirm the results in order to support more accurate and clear results.

Conclusions:

Under the conditions of this study, was found that, proper application of concentrated growth factors CGF as an osteoconductive material gave better enhancement in osteogenesis and acceleration in bone healing than Bisphosphonates BPH.

References:

1. Sanz M., Dahlin C., Apatzidou D., Artzi Z., Bozic D., Calciolari E., et al. Biomaterials and regenerative technologies used in bone regeneration in the craniomaxillofacial region: Consensus report of group 2 of the 15th European Workshop on Periodontology on Bone Regeneration. *J Clin Periodontol* 2019;46(21):82–91.
2. Sanz-Sánchez I., Sanz-Martín I., Ortiz-Vigón A., Molina A., Sanz M. Complications in bone-grafting procedures: Classification and management. *Periodontol* 2000 2022;88(1):86–102.
3. Sun S., Tao J., Sedghizadeh PP., Cherian P., Junka AF., Sodagar E., et al. Bisphosphonates for delivering drugs to bone. *Br J Pharmacol* 2021;178(9):2008–25.
4. Wang L., Wan M., Li Z., Zhong N., Liang D., Ge L. A comparative study of the effects of concentrated growth factors in two different forms

- on osteogenesis in vitro. *Mol Med Rep* 2019;20(2):1039–48.
5. Bonazza V., Borsani E., Buffoli B., Castrezzati S., Rezzani R., Rodella LF. How the different material and shape of the blood collection tube influences the Concentrated Growth Factors production. *Microsc Res Tech* 2016;79(12):1173–8.
 6. Srisubut S., Teerakapong A., Vattraphodes T., Taweekhaisupapong S. Effect of local delivery of alendronate on bone formation in bioactive glass grafting in rats. *Oral Surgery, Oral Med Oral Pathol Oral Radiol Endodontology* 2007;104(4):11–6.
 7. Barros Mourão C de A., Gheno E., Lourenço E., Barbosa RL., Kurtzman G., Javid K., et al. Characterization of a new membrane from concentrated growth factors associated with denaturized Albumin (Alb-CGF) for clinical applications: A preliminary study. *Int J Growth Factors Stem Cells Dent* 2018;1(2):64–9.
 8. Meraw SJ., Reeve CM. Qualitative Analysis of Peripheral Peri-Implant Bone and Influence of Alendronate Sodium on Early Bone Regeneration. *J Periodontol* 1999;70(10):1228–33.
 9. Chen H., Sun J., Hoemann CD., Lascau-Coman V., Ouyang W., McKee MD., et al. Drilling and microfracture lead to different bone structure and necrosis during bone-marrow stimulation for cartilage repair. *J Orthop Res* 2009;27(11):1432–8.
 10. Kim H-C., Song J-M., Kim C-J., Yoon S-Y., Kim I-R., Park B-S., et al. Combined effect of bisphosphonate and recombinant human bone morphogenetic protein 2 on bone healing of rat calvarial defects. *Maxillofac Plast Reconstr Surg* 2015;37(1):1–7.
 11. Grado GF de., Keller L., Idoux-Gillet Y., Wagner Q., Musset A-M., Benkirane-Jessel N., et al. Bone substitutes: a review of their characteristics, clinical use, and perspectives for large bone defects management: *J Tissue Eng* 2018;9:1–18.
 12. Naylor KE., McCloskey E V., Jacques RM., Peel NFA., Paggiosi MA., Gossiel F., et al. Clinical utility of bone turnover markers in monitoring the withdrawal of treatment with oral bisphosphonates in postmenopausal osteoporosis. *Osteoporos Int* 2019;30(4):917–22.
 13. Oktay EO., Demiralp B., Demiralp B., Senel S., Cevdet Akman A., Eratalay K., et al. Effects of Platelet-Rich Plasma and Chitosan Combination on Bone Regeneration in Experimental Rabbit Cranial Defects. *J Oral Implantol* 2010;36(3):175–84.
 14. Lang M., Zhou Z., Shi L., Niu J., Xu S., Lin W., et al. Influence of zoledronic acid on proliferation, migration, and apoptosis of vascular endothelial cells. *Br J Oral Maxillofac Surg* 2016;54(8):889–93.
 15. Yu NYC., Schindeler A., Tägil M., Ruys AJ., Little DG. Use of BMPs and bisphosphonates to improve bone fracture healing. *Front Biosci* 2012;4:2647–53.
 16. Chen X., Wang J., Yu L., Zhou J., Zheng D., Zhang B. Effect of Concentrated Growth Factor (CGF) on the Promotion of Osteogenesis in Bone Marrow Stromal Cells (BMSC) in vivo. *Sci Reports* 2018 81 2018;8(1):1–8.
 17. Durmuşlar MC., Balli U., Dede FÖ., Misir AF., Barış E., Kürkçü M., et al. Histological evaluation of the effect of concentrated growth factor on bone healing. *J Craniofac Surg* 2016;27(6):1494–7.
 18. Hauser M., Siegrist M., Keller I., Hofstetter W. Healing of fractures in osteoporotic bones in mice treated with bisphosphonates – A transcriptome analysis. *Bone* 2018;112(2):107–19.
 19. Sahin IO, Gokmenoglu C, Kara C. Effect of concentrated growth factor on osteoblast cell response. *J Stomatol Oral Maxillofac Surg*. 2018 Dec;119(6):477-481.
 20. Yüce MO., Adalı E., Işık G. The effect of concentrated growth factor (CGF) in the surgical treatment of medication-related osteonecrosis of the jaw (MRONJ) in osteoporosis patients: a randomized controlled study. *Clin Oral Investig* 2021;25(7):4529–41.
 21. Stavropoulos A., Wikesjö UME. Influence of defect dimensions on periodontal wound healing/regeneration in intrabony defects following implantation of a bovine bone biomaterial and provisions for guided tissue regeneration: an experimental study in the dog. *J Clin Periodontol* 2010;37(6):534–43.
 22. Simion M., Fontana F., Rasperini G., Maiorana C. Vertical ridge augmentation by expanded-polytetrafluoroethylene membrane and a combination of intraoral autogenous bone graft and deproteinized anorganic bovine bone (Bio Oss). *Clin Oral Implants Res* 2007;18(5):620–9.
 23. Schorn L., Fienitz T., Berndsen K., Kübler NR., Holtmann H., Rothamel D. The use of solvent-preserved human and bovine cancellous bone blocks for lateral defect augmentation - an experimental controlled study in vivo. *Head Face Med* 2021;17(1):1–9.